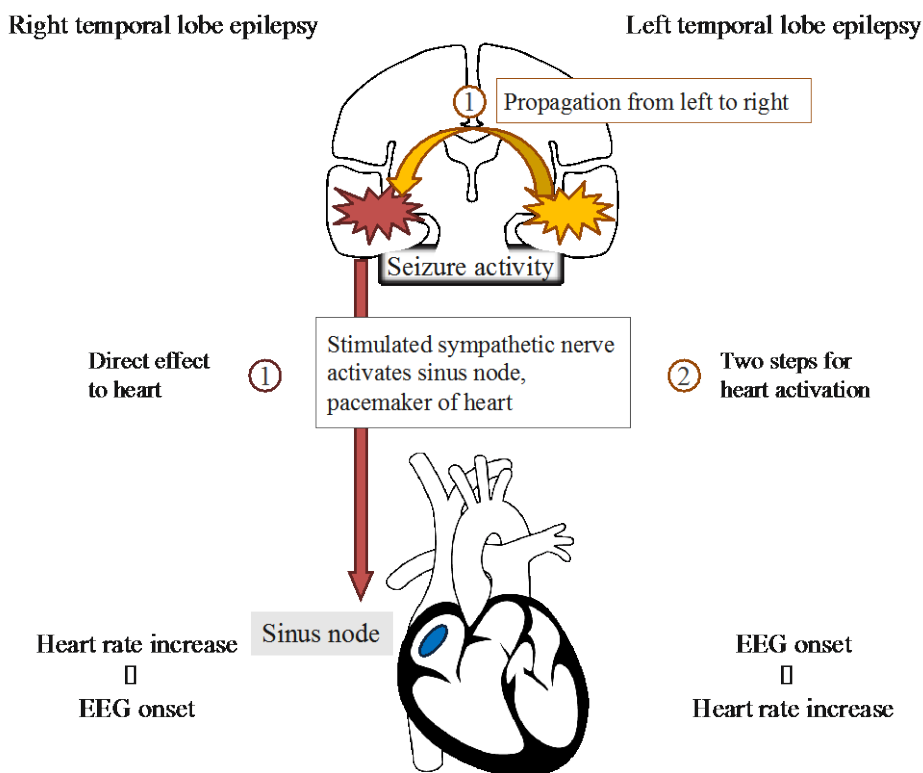


Timing of heart rate increase indicates laterality of seizure onset: useful tip for surgical indication of patients with temporal lobe epilepsy.

**Professor Nobukazu Nakasato**  
**Lecturer Kazutaka Jin**  
**Professor Masashi Aoki**

Professor Nobukazu Nakasato, lecturer Kazutaka Jin, and professor Masashi Aoki's research group at Tohoku University Graduate School of Medicine reported that onset time of heart rate increase was significantly earlier in right than left seizures in patients with temporal lobe epilepsy showing abnormal hippocampus. Timing of heart rate increase can be a useful lateralizing sign of temporal seizures. This result supports previous hypotheses that the right cerebral hemisphere is dominant in the sympathetic network. Furthermore, it may be useful for early seizure detection as well as precise presurgical evaluation. The results of this research were published in American Academy of Neurology's official journal, *Neurology*.



**Figure.** Propagation pathway of seizure activity from right and left temporal lobe to heart. Seizures arising from right temporal lobe make a direct effect on sinus node, pacemaker of heart, which results in earlier onset of heart rate increase. On the other hand, seizures arising from left temporal lobe first propagate to right temporal lobe, and then activate sinus node, which makes delayed onset of heart rate increase.

**Earlier tachycardia onset in right than left mesial temporal lobe seizures.**

Kato K, Jin K, Itabashi H, Iwasaki M, Kakisaka Y, Aoki M, Nakasato N.

*Neurology*. 2014 Sep 5. pii: 10.1212/WNL.0000000000000864. Epub 2014 Sep 5.



**Professor NAKASATO, Nobukazu**  
 Epileptology  
 nkst@med.tohoku.ac.jp  
<http://www.epilepsy.med.tohoku.ac.jp/>



**Lecturer JIN, Kazutaka**  
 Epileptology  
 jink@med.tohoku.ac.jp  
<http://www.med.tohoku.ac.jp/english/org/disability/63/index.html>



**Professor AOKI, Masashi**  
 Neurology  
 admin@em.neurol.med.tohoku.ac.jp  
<http://www.neurol.med.tohoku.ac.jp>